

in 06/2006 (CD4=2048). He received induction therapy (Ida+Ara-C+VP-16) and consolidation (Ida+Ara-C), obtaining CyCR. He received mobilizing treatment with A8 but failed PBSC collection. After 2 additional courses with HDAC is alive in CR (m+11). **Conclusions.** Intensive CT with HAART is feasible and allow to achieve CR in HIV+ pts with AML; HDT with stem cell rescue seems feasible and safe. However, caution is needed and additional studies are required to confirm feasibility and explore long-term outcome. **Acknowledgments.** This work was supported in part by FIRB (protocol number: RBAU01RLNB005 – 2004; D. Russo), progetto 60% 2005 (D.Russo) and COFIN 60% 2006.

PO-038

FUNGAL INFECTIONS IN ACUTE MYELOID LEUKEMIA PATIENTS TREATED WITH INDUCTION REGIMENS INCLUDING FLUDARABINE: A RETROSPECTIVE ANALYSIS OF 224 CASES

Malagola M,¹ Peli A,¹ Damiani D,² Candoni A,² Tiribelli M,² Martinelli G,³ Piccaluga PP,³ Paolini S,³ Lauria F,⁵ Bocchia M,⁵ Gobbi M,⁶ Pierri I,⁶ Zaccaria A,⁷ Zuffa E,⁷ Mazza P,⁸ Piccolo G,⁸ Gugliotta L,⁹ Bovini,⁹ Visani G,¹⁰ Skert C,¹ Bergonzi C,¹ Roccaro A,¹ Fili C,¹ Capuzzi E,¹ Fanin R,² Bacarani M,³ Russo D¹

¹Chair of Haematology, Unit of Blood Diseases and Cell Therapies, University of Brescia; ²Clinic of Haematology, University of Udine; ³Institute of Haematology and Medical Oncology Seràgnoli, University of Bologna; ⁴Chair of Statistics, University of Brescia; ⁵Chair of Haematology, University of Siena; ⁶Chair of Haematology, University of Genova; ⁷Division of Haematology, Ravenna; ⁸Division of Haematology, Taranto; ⁹Division of Haematology, Reggio Emilia; ¹⁰Division of Haematology, Pesaro, Italy

Infections are the major cause of morbidity and mortality of acute myeloid leukaemia (AML). Invasive Fungal Infections (IFIs) occur in at least 10 to 20% of the patients submitted to induction and consolidation treatments and are responsible for death during induction (DDI) up to the 5% of the cases. Furthermore, they may cause a delay in consolidation and intensification therapy with autologous or allogeneic stem cell transplantation and for these reasons they may contribute to increase the relapse rate. Among the risk factors for IFIs it has been included the use of Fludarabine (Fluda), which can induce severe and prolonged immunosuppression. In this study we retrospectively analyzed the infections occurred in 224 newly diagnosed AML patients, aged at least 60 years, consecutively treated with a Fluda containing induction regimen. One-hundred thirty-five patients were treated with FLAI (fludarabine + cytarabine + idarubicine) and 89 with FLAIE (fludarabine + cytarabine + idarubicine + etoposide). During induction phase, 134/224 (55%) patients experienced a fever of undetermined origin (FUO), the incidence of Gram negative and positive sepsis was 14% (31/224) and 22% (49/224) respectively and 38/224 (17%) patients developed a possible/probable IFI. In 9/224 patients (4%) a proven IFI was found (6 Aspergillosis and 3 Candida). Taking into consideration the long lasting immunosuppressive effect of Fluda, we collected the data of the incidence of infections during the first consolidation course (FLAI: n=70; high dose cytarabine: n=65; idarubicine and high dose cytarabine: n=89). The overall incidence of FUO was 29% (66/224), the number of Gram negative and positive sepsis was 53/224 (24%) and 49/224 (22%), respectively and 4/224 (2%) patients developed a proven IFI (3 Aspergillosis and 1 Candida). In all but one case, the fungal infections diagnosed during consolidation occurred in patients who developed an IFI during the previous induction therapy. These data, even though retrospectively collected, suggest that the use of a Fluda-based induction chemotherapy doesn't cause a high number of IFIs, neither during induction, nor during consolidation. In particular, the incidence of infective complications in our series of AML patients favourably compares to the one reported by other Authors with induction chemotherapy not including Fluda.

PO-039

ROLE OF DASATINIB IN PH+ POSITIVE ACUTE LYMPHOBLASTIC LEUKEMIA (ALL) AFTER IMATINIB-BASED THERAPY FAILURE: A CASE REPORT

Cortezzi A,¹ Pasquini MC,¹ Radaelli F,² Reda G,¹ Ripamonti F,¹ Gardellini A,¹ Intini D,¹ Spinelli O,³ Lambertenghi Deliliers G¹

¹U.O Hematology-1 and BMT Center Fondazione Ospedale Maggiore Policlinico, Mangiagalli, Regina Elena and Department of Medical Sciences, Università degli Studi, Milan; ²U.O Hematology-2 Fondazione Ospedale Maggiore Policlinico, Mangiagalli, Regina Elena, Department of Medical Sciences, Università degli Studi, Milan; ³Department of Hematology, Ospedali Riuniti di Bergamo, Italy

Ph+ ALL is largely associated with a dismal prognosis. Imatinib effectively blocks the bcr-abl-related tyrosine kinase activity, and therefore its use is now mandatory in the treatment of this disease. Dasatinib is a more potent abl kinase inhibitor, which appears to be active against 14 out of 15 known imatinib-resistant bcr-abl mutants. In November 2004 Ph+ ALL (p190) was diagnosed in a 60 years old man and induction therapy was soon started according to NILG protocol ALL09/2000-STI571, consisting of association of idarubicin, vincristin, prednisone and asparaginase plus triple-drug intrathecal therapy. Imatinib (600 mg/d) was administered 7 days/month. After 30 days complete remission (CR) was documented at morphologic, cytogenetic and molecular level. The patient was then consolidated with monthly cycles of chemotherapy plus imatinib up to August 2005, and submitted to cranial radio-prophylaxis. No related or matched unrelated donors were available. Starting on September 2005, 2 cycles of high dose chemotherapy with PBSC rescue were therefore administered, the patient being in continuous molecular CR. Maintenance therapy was initiated in December 2005 with daily oral 6-MP and weekly i.m. MTX plus imatinib 400 mg/d, 15 days per month. This therapy was complicated by recurrent, grade 4 trilineage hematologic toxicity. In May 2006, 18 months after diagnosis, molecular relapse was documented, followed one month later by cytogenetic (1/100 metaphase Ph+) and four months later by morphologic relapse (10% bone marrow blasts). Leukemic relapse ensued in the context of a severely hypoplastic bone marrow and of patient's performance status deterioration, thus precluding any further chemotherapy attempt. For these reasons dasatinib monotherapy (70 mg b.i.d.) was immediately started. No more than Grade 1 side effects were observed, a new morphologic CR was documented after one month therapy and it was confirmed two months later. After 3 months, dasatinib dosage was increased to 100 mg/d, its tolerability continuing to be excellent, a part from transitory and mild diarrhea. This increase of dose enabled a cytogenetic remission to be obtained on January 2007. On May 2007, that is 8+ months from dasatinib start, the patient remains in continuous cytogenetic remission. Figure 1 illustrates serial evaluation of MRD by means of real time PCR and documents the effectiveness of dasatinib-driven clearance of bcr/abl positive cells in this patient.

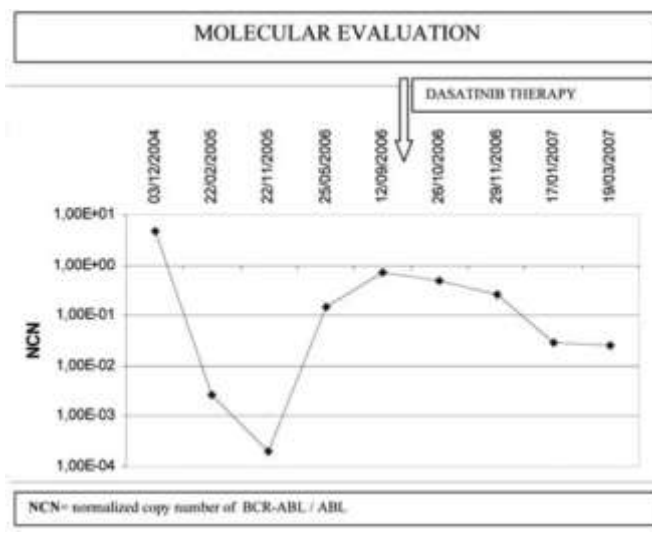


Figure 1.